

# Autoimmune Movement Disorders

Conor Fearon, PhD<sup>1</sup> Orna O'Toole, MD<sup>2</sup>

<sup>1</sup>Department of Neurology, Adelaide and Meath University Hospital, Tallaght, Dublin, Ireland

<sup>2</sup>Department of Neurology, Mercy University Hospital, Cork, Ireland

Address for correspondence Orna O'Toole, MD, Neurologist, Department of Neurology, Mercy University Hospital, Grenville Place, Cork, Ireland (e-mail: Ootoole7@gmail.com).

Semin Neurol 2018;38:316–329.

## Abstract

Autoimmune movement disorders are rare but potentially treatable entities. They can present with an excess or paucity of movement and may have other associated neurological symptoms. These disorders were originally recognized by their classic clinical presentations and the cancers associated with them. Recent emphasis has been targeted on associated, and sometimes causative, antibodies. Although some disorders have stereotypical presentations, the spectrum of abnormalities reported in association with antibodies is widening. Determining whether antibodies are incidental or pathogenic and, hence, foregoing or commencing immunotherapy treatment can be challenging for practicing neurologists. Physicians often have to make the decision to empirically treat patients while awaiting test results. Due to the lack of randomized controlled trials, the ideal immunotherapy treatments and regimens are unknown. Patients with intracellularly targeted antibodies tend to fare less well, while those with extracellularly targeted antibody disorders often respond to treatments reducing antibody production. This review aims to summarize reported adult-onset autoimmune movement disorders to date, and to provide a template for the workup and treatment of suspected disorders. Rarer antibodies that are not yet fully characterized, or reported in a few cases only, will not be covered in detail as these are not likely to be readily commercially available. Childhood disorders will be only be mentioned briefly in the discussion, as there is a separate article in this issue on autoimmune neurologic diseases in children.

## Keywords

- ▶ autoimmune
- ▶ encephalitis
- ▶ movement disorder
- ▶ paraneoplastic

Classic paraneoplastic autoimmune movement disorders such as cerebellar degeneration and opsoclonus-myoclonus syndrome (OMS) were first recognized and described by neurooncologists.<sup>1,2</sup> Antibodies were identified with some but not all of these conditions, indicating both B and/or T cell immunity could be involved to different extents. A trigger event—such as cancer or infection—stimulates the immune system to respond in an attempt to clear the foreign antigen. Tumors can express a wide variety of non-tumor-specific surface proteins, including neuronal antigens. Antibodies to these antigens are produced by the host and released into the bloodstream where they can be detected by the immune system. In addition, the production of cytotoxic T cells can cause direct peripheral nervous system and central nervous system (CNS) neuronal damage, and there

may also be direct autoantibody uptake by neurons. Antibodies and plasma cells capable of producing antibodies must gain access to the CNS—at least initially before subsequent CNS autoantibody production—but how this occurs remains poorly understood. It may be that some people have a “leaky blood–brain barrier” as with Apo E –/– mice, or that a secondary immunologic phenomenon disrupts blood–brain barrier integrity.<sup>3</sup> Antibodies, when identified, may be directed against intracellular (aka nuclear, nucleolar, or cytoplasmic) or extracellular (aka cell surface, synaptic) antigens.<sup>4,5</sup> Antibodies directed against intracellular antigens are most often associated with malignancy, extracellular less so, with notable exceptions such as *N*-methyl-D-aspartate receptor (NMDAR) antibody encephalitis.<sup>4,6–8</sup> Damage to the nervous system in

Issue Theme Autoimmune Neurology;  
Guest Editor, Stacey L. Clardy, MD, PhD.

Copyright © 2018 by Thieme Medical Publishers, Inc., 333 Seventh Avenue, New York, NY 10001, USA.  
Tel: +1(212) 584-4662.

DOI <https://doi.org/10.1055/s-0038-1660851>.  
ISSN 0271-8235.

the presence of cancer is, at least in part, mediated by an early cytotoxic CD8+ T cell attack (►Fig. 1);<sup>9-12</sup> further research is needed to determine if there is also neural uptake of pathogenic antibodies. These conditions often respond poorly to immunotherapy, and stabilization (rather than reversal) of disability is usually the best outcome, although diagnosis is often later in the disease course, and it is unknown if better outcomes could be possible with very early initiation of treatment.<sup>11,13</sup> Antibodies that target cell surface antigens, such as anti-NMDAR and anti-leucine-rich glioma-inactivated 1 (LGI1) antibodies, are directly pathogenic, with clear demonstration of alteration of synaptic function by the antibodies, with less T cell-mediated tissue destruction (►Fig. 1).<sup>14-16</sup> Cancer association is weaker (but not absent) with these antibodies, and response to immunotherapy is generally far superior, though the disease course can be fluctuant with relapses.<sup>17</sup>

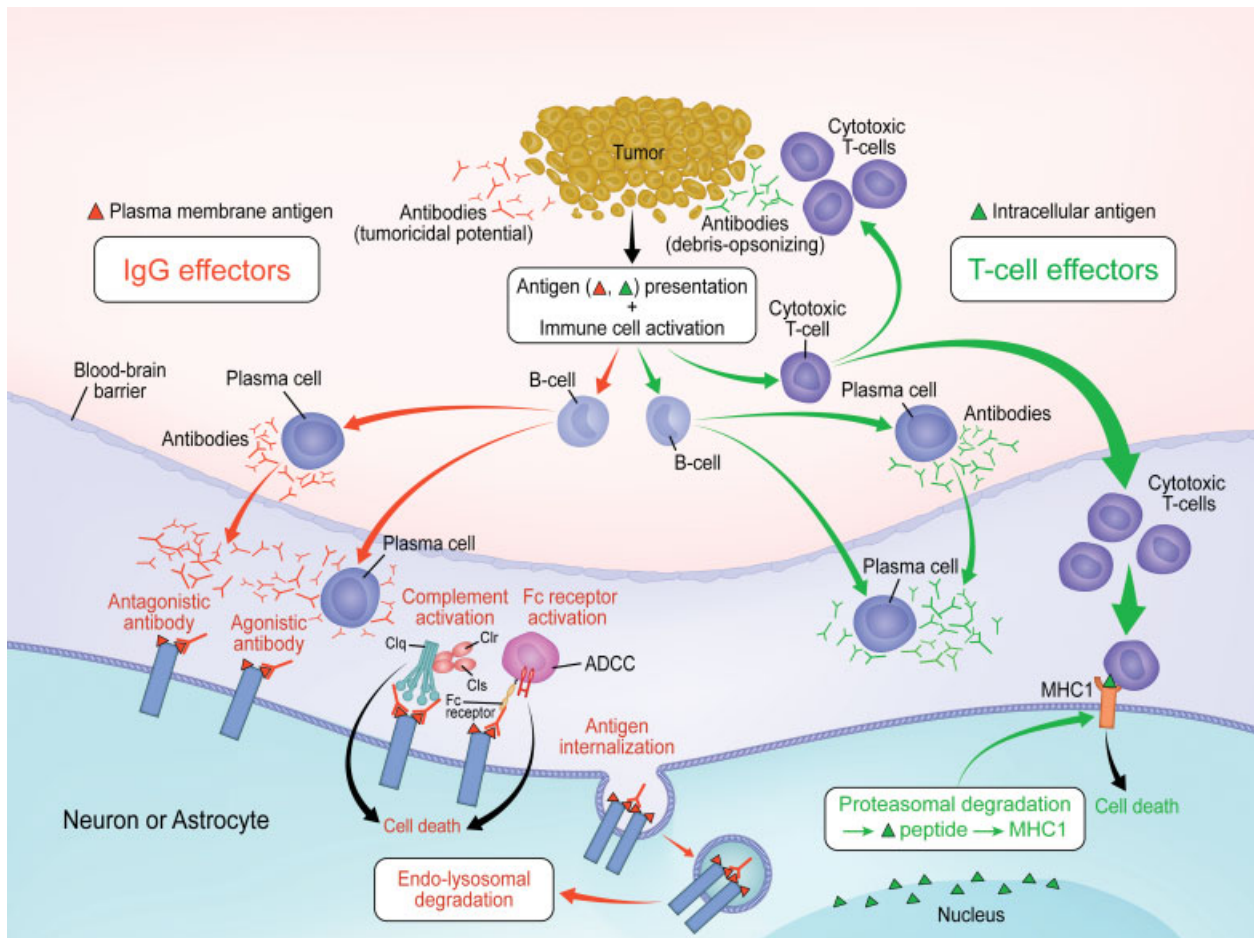
Our understanding of this emerging area of autoimmune movement disorders in neurology is growing, along with the list of associated autoantibodies. At present, epidemiological and treatment data on these conditions remain limited. This review covers the current autoimmune movement disorders

literature. We describe the features suspicious of an autoimmune movement disorder (►Table 1), and the approach to evaluation. Next, we describe some of the features of previously reported autoimmune movement disorders. We outline in table form both the movement disorders (►Table 2) and the known characterized antibodies associated with movement disorders (►Table 3). Finally, we discuss treatment strategies.

### Features and Workup

Pure, isolated autoimmune movement disorders are rare, and other etiologies should always be considered during the workup. Cerebellar ataxia, chorea, and OMS are the most well-known disorders. Most cases will have additional evidence of neurological dysfunction, such as encephalopathy or peripheral neuropathy. ►Table 1 suggests features that should prompt one to consider an autoimmune etiology.

If an autoimmune movement disorder is suspected, the patient should have several key tests to look for supportive evidence; such evidence can be useful later to ascertain treatment success by comparing pre- and posttreatment



**Fig. 1** Neural antigens are expressed at the surface of a tumor and presented to B and T cells inciting an immune response. Antibodies targeting neuron or astrocyte surface antigens (red) cause alteration of the function of receptors on the cell surface such as receptor internalization. Antibodies targeting intracellular antigens do not usually affect neuronal function, but the T cell response causes destruction of neuron or astrocyte tissue that is often permanent. Antibodies of both types are detectable in the serum and/or CSF of patients, allowing confirmation of an autoimmune process. (Reproduced with permission from McKeon and Pittock,<sup>4</sup> Figure 1, page 38.)

**Table 1** When to suspect autoimmune movement disorder

When to suspect an autoimmune etiology
Female gender
Subacute onset
Fluctuating course
Multifocal neurological disease
Personal or family history of autoimmunity
Personal history of cancer or suspicion of new cancer
Abnormal supportive tests, i.e., CSF, imaging
Response to immunotherapy

Abbreviation: CSF, cerebrospinal fluid.

results. Serum antibody testing should be sent, ideally with a matched cerebrospinal fluid (CSF) sample. This is particularly true in NMDAR and AMPAR ( $\alpha$ -amino-3-hydroxy-5-methyl-4-isoxazolepropionic acid receptor) syndromes where occasionally antibody-negative serum but antibody-positive CSF patients have been described.<sup>18–21</sup> There is a trend for laboratories to provide testing panels of antibodies for different disorders, and it is likely in the future there may be specific movement disorder panels. It is important to realize that when “a paraneoplastic panel” is ordered, many commercial laboratories will only report on several common antibodies, and they may not have tested for a specific or unusual antibody of interest unless included in the “panel.” Conversation with the testing laboratory can be useful to clarify what testing will be done and the anticipated turnaround time for reporting results. Approaching one of the large academic neuroimmunology laboratories with interesting or complex cases and arranging more extensive testing is sometimes worthwhile. In addition to testing antibodies, CSF should be evaluated for leukocytosis, raised protein, increased IgG index, and oligoclonal bands. Magnetic resonance imaging (MRI) of the brain and/or spinal cord should be performed with and without gadolinium, looking for evidence of limbic encephalitis and/or myelitis which may accompany the disorder, and also to exclude other diagnoses. T2 fluid-attenuated inversion recovery (FLAIR) and diffusion-weighted imaging (DWI) sequences are particularly useful for both temporal and extratemporal abnormalities.<sup>22</sup> Electroencephalogram (EEG) should be performed to look for evidence of encephalopathy or seizure activity. Some disorders, such as faciobrachial dystonic seizures with LGI1,<sup>23</sup> and extreme delta brush on EEG with NMDAR antibodies<sup>24</sup> are characteristic. When available, a movement disorder laboratory evaluation can be valuable in detecting features of hyperekplexia, stiff person syndrome (SPS), or myoclonus. If any of the above tests are supportive, then a thorough age-appropriate search for cancer should be performed, including a repeat comprehensive physical examination. Certain antibodies, when positive, can guide the search for malignancy; for example, PCA-1/anti-Yo is highly associated with gynecological cancer in females. Mammography, testicular ultrasound, pelvic ultrasound, computed tomography (CT) of the chest/abdomen/pelvis, gastroscopy,

colonoscopy, digital rectal exam, serum prostate-specific antigen, and cervical smear testing should all be considered in the appropriate clinical contexts. If no cancer is identified, but suspicion of malignancy is high, or an identified antibody is highly associated with cancer, then positron emission tomography-computed tomography (PET-CT) of the body should be considered and potentially repeated serially, as both the movement disorder and the antibody can predate the appearance of a recognizable tumor. Once routine testing is performed, PET-CT increases the sensitivity of diagnosis in 10% of cases.<sup>25</sup> The European Federation of Neurological Societies (EFNS) has published guidelines on cancer screening in this setting.<sup>26</sup> Neuropsychological testing may also be helpful when available if the patient has associated cognitive impairment. Sweat testing, autonomic and peripheral nerve studies, or bowel motility studies may be considered if there are features of involvement of these systems in addition to a movement disorder. Video can be extremely valuable in documenting movement disorders over time. It may be helpful to follow any objectively abnormal test results pre- and post-treatment as an unbiased assessment of immunotherapy effect.

## Movement Disorders

### Catatonia

It is an abnormality of movement and behavior resulting in immobility and stupor with waxy flexibility, catalepsy, and stereotypy. Patients may be mute and withdrawn or agitated. The cause may be psychiatric or neurologic, and it is essential to not just clinically diagnose the features of catatonia, but to determine an etiology for the catatonia. NMDAR encephalitis is now a commonly recognized cause of catatonia.<sup>27</sup> Although high-dose benzodiazepines can transiently improve the patient in all-cause catatonia, if the cause is autoimmune, then immunotherapy is required to treat the condition and prevent progression. If a tumor, such as an ovarian teratoma, is identified, symptoms are more likely to resolve upon removal. Immunotherapy is usually also required in this setting.

### Cerebellar Ataxia

Ataxia is an impairment of voluntary coordination of muscle movements most frequently associated with cerebellar disease. Autoimmune cerebellar dysfunction tends to temporally present midway between the rapid onset of a stroke and the slow onset of a genetic disorder. Patients may have associated dizziness, diplopia, oscillopsia, vertigo, or dysarthria.<sup>28,29</sup> Those with nonparaneoplastic disease can do well with immunotherapy treatment. Patients with paraneoplastic cerebellar disease are usually extremely disabled early in their clinical course, or have already progressed substantially prior to diagnosis.<sup>28</sup> The originally described PCA-1/anti-Yo antibody disorder occurs virtually exclusively in females with breast, uterine, and ovarian cancers, and response to immunotherapy in this disorder is generally extremely poor. Cytotoxic immunotherapy such as cyclophosphamide is often initiated with a goal of slowing or halting progression, but seldom reverses existing disability. Occasionally, classic paraneoplastic

antibodies coexist with extracellular antibodies such as voltage-gated calcium channel (VGCC) antibodies; these patients may respond partially to immunotherapies such as rituximab, which would not usually be effective in disorders with pure intracellular antibodies only.<sup>30</sup> The detection of coexisting antibodies is the benefit of antibody screening panels, as opposed to testing for individual antibodies. For example, there are over 30 antibodies now described in association with autoimmune cerebellar disease—some better characterized than others and some where only a few cases have been reported; we include in our table the most well-characterized and reported antibodies to date at the time of publication. The majority of laboratories will only test for the most commonly associated antibodies, and thus supportive evidence of an autoimmune etiology, such as oligoclonal bands in the CSF, can be helpful in situations where neural antibody testing is limited.

In addition to ataxia, patients with VGCC antibodies may have overlapping features of Lambert–Eaton myasthenic syndrome.<sup>28,31–35</sup> Ataxia in glutamic acid decarboxylase (GAD65) antibody–positive patients may respond to immunotherapy, possibly due to the coexistence of another extracellular antibody in tandem (such as the glycine receptor [GlyR] antibody); there may also be overlap of cerebellar ataxia with stiff person syndrome (SPS) and progressive encephalomyelitis with rigidity and myoclonus (PERM) in these cases. Only 12% of pure GAD65 antibody ataxia is associated with cancer.<sup>34–36</sup> Cerebellar ataxia has also been reported in association with antibodies to glial fibrillary acidic protein (GFAP).<sup>37</sup> These antibodies can cause a broad range of neurological syndromes and are found in association with malignancy in approximately one-third of cases. CASPR2-associated ataxia can present as an episodic disorder, with initially reported attacks triggered by postural changes and/or emotions<sup>38</sup> both CASPR2 and GFAP antibody–positive patients respond to immunotherapy when caught early. Finally, NMDAR antibodies have also been described rarely with ataxia without other classic NMDAR encephalitis features.<sup>19</sup>

Celiac disease–associated ataxia is controversial and likely multifactorial. Ninety percent of cases occur in the absence of gastrointestinal symptoms of celiac disease, but other systemic autoimmune disorders and micronutrient deficiencies often coexist that may be directly or indirectly associated with ataxia. According to the literature, cerebellar atrophy is present in over half of patients by presentation. If identified early, precerebellar atrophy ataxia may be reversible by adhering to a gluten-free diet.<sup>39</sup> Case reports suggest that lower limb ataxic predominance with prominent gait disruption is common.<sup>39</sup>

In patients with a reported clinical diagnosis of SREAT (steroid-responsive encephalopathy associated with autoimmune thyroiditis, previously known as Hashimoto's encephalopathy), up to 28% may present with cerebellar ataxia.<sup>39</sup> Onset can be acute or insidious, with a predominantly truncal ataxia and nystagmus.<sup>39</sup> Cerebellar atrophy is often absent. Complete remission with steroids occurs in almost all cases, and this diagnosis should only be entertained when all

known neural antibodies have been tested for and excluded, as it is possible that many historical cases of SREAT may have been caused by previously unknown or as-yet unidentified neural antibodies. The presence of thyroid antibodies in SREAT patients—and any patients with systemic or neurologic autoimmunity—indicates that the patient has a predisposition to autoimmunity, but it is unlikely that the thyroid antibodies themselves are pathogenic.

### Chorea

Chorea (from the Greek, to dance) consists of involuntary brief jerky movements randomly moving from one part of the body to another in an unpredictable fashion. It can be associated with athetosis (choreoathetosis) or other hyperkinetic movement disorders under the umbrella term dyskinesia. Hence, both disorders are grouped together in **Table 2**. Autoimmune disease is the second most common cause of adult-onset chorea, after Huntington's disease.<sup>40</sup> In children, Sydenham's chorea (SC) accounts for the majority of cases historically, but this condition is rare in adults and will not be covered in detail.<sup>41</sup>

Adult-onset autoimmune chorea can be paraneoplastic or nonparaneoplastic.<sup>40,42</sup> Paraneoplastic chorea is more likely in older, male patients with generalized chorea and other neurological features such as peripheral neuropathy.<sup>40</sup> Collapsin-response-mediated protein-5 (CRMP-5) antibody is the most common paraneoplastic association, typically with small cell lung carcinoma (SCLC) or thymoma.<sup>43–45</sup> CRMP-5-associated chorea is usually part of a multifocal neurological disorder, which can include optic neuritis/retinitis, encephalopathy, ataxia, peripheral neuropathy, and, rarely, myelopathy.<sup>43,44</sup> MRI may show FLAIR hyperintensities in the basal ganglia, limbic regions, brainstem, and white matter, or may be normal.<sup>46</sup> The next most common paraneoplastic chorea is associated with antineuronal nuclear antibody type 1 (ANNA-1)/anti-Hu, also commonly associated with SCLC.<sup>11</sup> Nonparaneoplastic chorea is more likely in younger, female patients with isolated chorea; often, this is a hemichorea rather than generalized chorea.<sup>40</sup> Both NMDAR and neurexin-3 $\alpha$  encephalitis can be associated with complex movement disorders: frequently chorea, particularly orofacial chorea/dyskinesia, which may continue while the patient is comatose. Both conditions are also associated with autonomic instability, central hypoventilation, and behavioral and cognitive disturbance with seizures. Neurexin-3 $\alpha$  antibodies have only recently been described in five female patients, and are probably less common than NMDAR antibodies as a cause of encephalitis. Prodromal fever and diarrhea may be useful clues. No tumors have yet been associated with neurexin-3 $\alpha$  antibodies.<sup>47–49</sup> Chorea may be an especially prominent feature when NMDAR antibodies are detected 2 to 6 weeks post-herpesviral infectious encephalitis,<sup>50,51</sup> and also may be the only finding in children with NMDAR antibodies. An underlying ovarian teratoma is present in up to 50% of postpubescent females with NMDAR antibodies, but malignancy is rare in prepubescent children and men.<sup>52</sup>

Chorea can also be found in association with CASPR2, LGI1, and GAD65 antibodies. These associations tend to have a more favorable response to immunotherapy and are less frequently associated with cancer. One nonparaneoplastic

**Table 2** Movement disorders and their associated antibodies

Movement disorders	Extracellular	Intracellular	Nonneuronal antibody associations	Comment
Ataxia	AMPA GABAR-A GABAR-B GFAP mGluR1 NMDAR VGCC VGKC complex (CASPR2)	ANNA-1 ANNA-2 (Ri) ANNA-3 CRMP-5 GAD65 Homer-3 ITPR-1 Ma2 PCA-1 (Yo) PCA-2 PCA-Tr Zic-4	Gliadin Endomysial	Celiac ataxia is likely multifactorial
Athetosis	AMPA			
Ballism		CRMP-5		
Cataplexy		Ma-2		
Catatonia	NMDAR			
Chorea/choreoathetosis	AMPA GABAR-A GABAR-B Glycine R IgLON5 Neurexin-3 $\alpha$ NMDAR VGKC complex (LGI1/CASPR2)	ANNA-1 (Hu) CRMP-5 GAD65 PCA-1 (Yo)	APLS ASO SSA/SSB (Ro/La) TPO	
Dystonia	AMPA GABAR-A Glycine R tetanus-like trismus and opisthotonus described with Glycine and ANNA-2 receptor antibodies NMDAR VGKC complex (LGI1)	ANNA-2 (Ri) CRMP-5 GAD65 Ma2	APLS Abs SSA/SSB (Ro/La)	Tetanus-like trismus and opisthotonus
Hyperekplexia	Glycine	Amphiphysin GAD65		
Myoclonus	AMPA Glycine R Neurexin-3 $\alpha$ VGKC complex (LGI1)	Amphiphysin	TPO	
Opsoclonus-myoclonus	Glycine R DPPX GABAR-A GABAR-B Ganglionic AChR HNK-1 NMDAR	ANNA-2 (Ri) Ma-1 Ma-2 CRMP-5 Zic-4 GAD65		Most is antibody negative
Parkinsonism	DPPX GAD-65 Glycine R IgLON5 LGI1 VGKC (pre-LGI1 and CASPR2)	ANNA-2(Ri) CRMP-5 GAD65 Ma-1 Ma-2*	APLS TPO	Supranuclear gaze palsy
Pseudoathetosis	VGKC complex (CASPR2)	ANNA-1 (Hu)		
PERM/stiff person syndrome	AMPA DPPX GABAR-A Gephyrin Glycine R $\alpha$ 1 P/Q and N-type calcium channel VGKC (pre-LGI1 and CASPR2)	GAD65 Amphiphysin	TPO	
Tics	VGKC complex (LGI1)	D2R (controversial)	ASO	
Tremor	AMPA DPPX GABAR-B GFAP Glycine R mGluR1 P/Q and N-type calcium channel VGKC complex (LGI1/CASPR2)	ANNA-1 (Hu) CRMP-5 GAD65 (palatal)* Ma1 Ma2 PCA-1 PCA-2 PCA-Tr ZIC-4	APLS Antigliadin/TTG SSA/SSB TPO	Palatal tremor

**Table 3** Antibodies with associated movement disorder and cancers

Antibodies (antigens)	Movement disorders	Associated features	Associated tumor
AGNA (Sox-1)	Ataxia	Brainstem encephalitis, Lambert–Eaton syndrome, peripheral (sensory) neuropathy	Lung cancer
AMPA	Athetosis, chorea, dystonia, myoclonus, PERM/SPS, tremor	Amnesia, coma, encephalitis, eye movement abnormalities, psychiatric disturbance	Breast cancer, small cell lung cancer, thymoma, thymic cancer
Amphiphysin	Hyperekplexia, myoclonus, PERM/SPS	Myelopathy, sensory ganglionopathy	Breast cancer, small cell lung cancer
ANNA-1 (Hu)	Ataxia, chorea, pseudoathetosis, tremor	Brainstem encephalitis, gut dysmotility, myelitis, peripheral neuropathy, sensorineural deafness	Bladder cancer, small cell lung cancer
ANNA-2 (Ri)	Ataxia, dystonia, opsoclonus-myoclonus, parkinsonism	Brainstem or limbic encephalitis, myelitis	Breast cancer, small cell lung cancer
ANNA-3	Ataxia	Brainstem or limbic encephalitis, myelitis, peripheral neuropathy	Small cell lung cancer
CASPR-2 (VGKC complex)	Ataxia, chorea, parkinsonism, PERM/SPS, pseudoathetosis, tremor	Encephalopathy, cognitive and/or psychiatric disturbance, neuro-myotonia, peripheral neuropathy, seizures	Thymoma (30%)
CRMP5	Ataxia, ballism, chorea, dystonia, opsoclonus-myoclonus, tremor	Encephalopathy, myelitis, optic neuritis, peripheral neuropathy	NHL, small cell lung cancer, thymoma, tonsillar cancer
DPPX	Hyperekplexia, opsoclonus-myoclonus, parkinsonism, PERM/SPS, tremor	Cognitive impairment preceded by diarrhea, dysautonomia, encephalopathy, periodic limb movements of sleep	Leukemia, lymphoma
DR2	Chorea, dyskinesia, parkinsonism, tics	Encephalopathy/encephalitis in children	N/A
GABAR-A	Ataxia, dystonia, opsoclonus-myoclonus, PERM/SPS	Brainstem encephalitis, chorea, encephalopathy, seizures	Hodgkin's lymphoma (rare)
GABAR-B	Ataxia, chorea, opsoclonus-myoclonus, tremor	Agrypnia excitata, brainstem encephalitis, coma, encephalopathy	Breast cancer, small cell lung cancer, thymoma
GAD65	Ataxia, chorea, dystonia, hyperekplexia, parkinsonism, PERM/SPS, tremor	Limbic encephalitis, insulin-dependent diabetes mellitus, seizures (can be focal onset)	Breast cancer, colon cancer, lymphoma, renal cell cancer, thymoma
Gephyrin	PERM/SPS	Brainstem encephalitis	Mediastinal tumors (single case only)
GFAP	Ataxia, tremor	Cognitive disturbance, encephalopathy, meningoencephalitis, optic nerve edema, seizures	Varied (34%): bladder cancer, breast cancer, carcinoid, colon cancer, Hodgkin's lymphoma, lung cancer, stomach cancer, melanoma, myeloma, ovarian teratoma, parotid cancer, prostate cancer, renal cell cancer, teratoma
Glycine	Chorea, dystonia, hyperekplexia, opisthotonus, opsoclonus-myoclonus, parkinsonism, PERM/SPS, tremor, trismus	Autonomic dysfunction, brainstem encephalitis, encephalopathy, eye movement abnormality	Breast cancer, Hodgkin's leukemia, small cell lung cancer, thymoma (<10%)
HNK-1	Opsoclonus-myoclonus (rare)	Encephalopathy	Lung cancer (3 patients only)
Homer-3	Ataxia (rare)	Encephalopathy, seizures	N/A (4 cases only)
IgLON-5	Ataxia, chorea, parkinsonism, SPS	Autonomic dysfunction, cognitive impairment, eye movement abnormality, OSA, REM and non-REM sleep behavior disorders, stridor	Breast cancer, NHL, prostate cancer
ITPR-1	Ataxia (rare)	Peripheral neuropathy	Breast cancer with BRCA1

(Continued)

**Table 3** (Continued)

Antibodies (antigens)	Movement disorders	Associated features	Associated tumor
LGI1	Chorea, dyskinesia, dystonia, faciobrachial dystonic seizures, myoclonus, parkinsonism, PERM/SPS, tics tremor	Bradycardia, cognitive impairment, hyponatremia, limbic encephalitis, seizures	Carcinoid, mesothelioma, neuroendocrine pancreatic tumor, rectal carcinoma
Ma-1	Opsoclonus-myoclonus	Brainstem encephalitis, limbic encephalitis	Bladder cancer
Ma-2/Ta	Dystonia, opsoclonus-myoclonus, parkinsonism	Brainstem encephalitis, encephalopathy, eyelid opening apraxia, hypothalamic dysfunction, limbic encephalitis, myelitis, radiculitis, plexitis, narcolepsy type syndrome, REMSBD, supranuclear palsy, weight gain	Lung cancer, testicular cancer
mGluR-1	Ataxia, tremor	Prodromal dysgeusia	Hodgkin's lymphoma, prostate cancer
NMDAR	Ataxia, athetosis, catatonia, chorea, dystonia, opsoclonus-myoclonus, parkinsonism	Autonomic dysfunction, cognitive impairment, coma, encephalopathy, psychiatric disturbance, seizures	Ovarian teratoma (40%), breast cancer, lung cancer, extra ovarian teratoma, ovarian cancer, pancreatic cancer, testicular cancer
Neurexin-3α	Myoclonus, orofacial dyskinesia	Autonomic dysfunction, cognitive impairment, coma, diarrhea, encephalopathy, prodromal fever, seizures	N/A
PCA-1 (Yo)	Ataxia, chorea, tremor	Brainstem encephalitis, peripheral neuropathy	Gynecological cancer
PCA-2	Ataxia, tremor	Brainstem encephalitis, encephalopathy, Lambert-Eaton syndrome, limbic encephalitis, myelitis, peripheral neuropathy	Small cell lung cancer
PCA-Tr	Ataxia, tremor	Encephalopathy, eye movement or pupillary abnormality, peripheral neuropathy	Hodgkin's lymphoma
P/Q and N (VGCC)	Ataxia, tremor	Lambert-Eaton myasthenic syndrome, limbic encephalitis	Small cell lung cancer
ZIC-4	Ataxia, opsoclonus-myoclonus	Lambert-Eaton myasthenic syndrome (rare)	Small cell lung cancer, ovarian carcinoma

Abbreviations: NHL, non-Hodgkin's lymphoma; PERM, progressive encephalomyelitis with rigidity; SPS, stiff person syndrome.

Note: Agrypnia excitata: insomnia, motor, and autonomic hyperactivation; REMSBD REM: sleep behavior disturbance.

chorea with a potentially worse prognosis is the recently described IgLON5.<sup>53,54</sup> This is usually a multifocal condition associated with prominent sleep disruption. Associated ataxia, dysarthria, dysphagia, and parkinsonism are described, with rapid progression to death in some cases. Nonparaneoplastic chorea in association with recent streptococcal infection (SC), systemic lupus erythematosus, and antiphospholipid syndrome is not associated with cancer, and may be responsive to immunotherapy. SC is rare in adults, but in children it may be associated with positive D2 antibodies targeting dopamine receptors, though this is controversial,<sup>55</sup> and it may be prudent to test suspected cases of SC for other contributing or causal etiologies.

### Dystonia

Dystonia is characterized by sustained abnormal posturing and twisting of the axial or limb muscles. It may be associated with

abnormal repetitive movements such as tremor, an in such cases the movement is characterized as a "dystonic tremor."<sup>56</sup> Although more classically associated with OMS, ANNA-2/anti-Ri antibody can be found in patients with painful jaw dystonia, axial/neck dystonia, and laryngospasm, potentially resulting in malnutrition, respiratory distress, and even death.<sup>57</sup> Breast and lung cancer are most commonly associated with ANNA-2/anti-Ri antibodies. MRI may be normal or demonstrate T2 hyperintensity in the pons and temporal regions. The pathological target appears to be the brainstem reticular formation, where infiltrations of CD8+ T lymphocytes have been observed on postmortem examination.<sup>57</sup> Unlike ANNA-1/anti-Hu and PCA-1/anti-Yo antibodies, patients with ANNA-2/anti-Ri paraneoplastic syndromes frequently demonstrate improvement if treated promptly. This is consistent with in vitro observations that while all three antibodies are taken up by viable neurons in slice cultures, antibodies to ANNA-1/anti-Hu and PCA-1/anti-Yo

cause neuronal death and ANNA-2/anti-Ri antibodies initially induce only reversible neuronal dysfunction, rather than early cell death.<sup>58</sup>

Dystonia in association with NMDAR is more common in children (with associated psychomotor agitation and dyskinesia), but rare adult cases have been reported.<sup>59,60</sup> Limb and oromandibular dystonia are most common, though oculogyric crisis is not infrequently seen, followed by generalized dystonia sometimes seen with other movement disorders.<sup>61</sup> In these cases, striatal T2 hyperintensities may be seen on MRI brain.<sup>62</sup> As mentioned earlier, ovarian teratoma may be identified in adult female patients more than children.<sup>63</sup>

Although there is much debate as to whether they represent a seizure or a movement disorder, faciobrachial dystonic movements described with LGI1 antibodies warrant discussion. These involuntary, brief but extremely frequent, contractions of unilateral face, arm, and occasionally leg last less than 2 seconds and can occur up to 100 times per day.<sup>64</sup> These movements can be subtle but are highly specific for LGI1 encephalitis and occur early in the disease course. Brief loss of awareness may be preceded by an aura of fear or difficulty speaking. MRI may show basal ganglia hyperintensities.<sup>65</sup> Ictal seizure activity or focal slowing is noted on the EEG. Patients respond better to early initiation of immunotherapy rather than anticonvulsant monotherapy, though both are used in combined treatment.<sup>23</sup>

Dystonia has also been reported uncommonly in association with GAD65 antibodies,<sup>66,67</sup> GlyR antibodies,<sup>68</sup> CRMP-5 antibodies,<sup>45</sup> antiphospholipid antibodies (often in association with parkinsonism),<sup>69,70</sup> and in Sjögren's syndrome.<sup>71,72</sup>

### Myoclonus

The term myoclonus describes brief, electric shock-like jerks that can be focal, multifocal, or generalized. Myoclonus has been described earlier in OMS, and will also be described later in this review in the context of PERM. Isolated myoclonus can occur as a *forme fruste* of OMS, but autoimmune myoclonus can also occur as an independent entity.

In a case series of patients with IgLON5 autoantibodies, 3 of 26 patients had myoclonus in conjunction with other neurological features.<sup>54</sup> The recently described clinical spectrum of GFAP autoimmunity included a 15-year-old patient with diffuse myoclonus.<sup>73</sup> Dipeptidyl-peptidase-like protein-6 (DPPX) antibody-positive patients can have severe myoclonus in conjunction with dysautonomia and diarrhea.<sup>74,75</sup> Myoclonus can also mimic Creutzfeldt-Jakob disease in the setting of LGI1 antibodies with similar FLAIR and DWI changes seen cortically on MRI in both disorders.<sup>76</sup> CASPR2 is associated with bilateral lower limb myoclonus similar to orthostatic tremor in older gentlemen. They may also have fasciculations, neuropathic pain and cognitive impairment responsive to immune therapy.<sup>77</sup>

### Opsoclonus-Myoclonus Syndrome

OMS is an autoimmune disorder characterized by the acute or subacute onset of opsoclonus (chaotic, conjugate saccadic eye movements in all directions of gaze without intersaccadic intervals), myoclonus (brief electric shock-like jerks which

can be focal, multifocal, or generalized), and ataxia, often with coexistent mood/behavioral changes or sleep disturbance. Some patients may have only opsoclonus or whole-body myoclonus without other features.<sup>78,79</sup> Autoantibodies are often negative, imaging is usually normal, and CSF may show raised protein, lymphocytic pleocytosis, and oligoclonal bands.

Although OMS can be caused by metabolic derangements or drug or toxin exposure, the pathogenesis is most frequently immune mediated.<sup>80</sup> Autoantibodies are isolated in less than 20% of cases<sup>81</sup> but immunotherapy is usually effective. Presumptive targets include the cerebellum and pons (specifically the pontine omnipause neurons). Post-mortem studies demonstrate mild perivascular lymphocytic inflammation in these areas without significant neuronal destruction, suggesting the immune attack is not T cell mediated.<sup>82,83</sup> OMS can also be idiopathic, paraneoplastic, or parainfectious.<sup>81</sup> In children, an underlying neuroblastoma is found in 50% of cases.<sup>84</sup> In adults, 15 to 40% of cases are paraneoplastic, especially in patients older than 40 years. SCLC, breast adenocarcinoma, ovarian teratoma, testicular seminoma, non-SCLC, gastric, thymic, renal cell, and oropharyngeal carcinoma are all described in patients with this disorder.<sup>81,85</sup> OMS precedes the discovery of a tumor in 70% of cases.<sup>81</sup>

The only consistent antibody association is ANNA-2 in patients with breast adenocarcinoma.<sup>86</sup> Ma1, Ma2, CRMP-5, and Zic4 and rarely GAD65<sup>81,87,88</sup> antibodies have been reported with this movement disorder. Similarly, CASPR2, DPPX, GABAR-A, GABAR-B, ganglionic ACh receptor, HNK-1, GlyR, LGI1, and NMDAR antibodies are all associated with OMS.<sup>81,89,90</sup> Females with NMDAR antibody and myoclonus should be checked for ovarian teratoma. HNK-1 antibodies are common in lung cancer patients with OMS.<sup>81</sup> GlyR antibody can also be associated with lung cancer in this context; pontine omnipause neurons, which tonically inhibit saccadic bursts of eye movements, are glycinergic.<sup>91</sup> Regardless of the presence or absence of antibodies or cancer, these patients are unusual in that all can respond to immunotherapy, though less well in paraneoplastic cases.<sup>85</sup>

In younger adults, parainfectious and idiopathic OMS are more common. These patients more frequently experience a viral prodrome before the onset of the movement disorder. Response to immunotherapy is usually good.<sup>81</sup> These patients have fewer additional neurological features and typically recover within 4 to 6 weeks of treatment.<sup>85</sup>

### Parkinsonism

Classic idiopathic Parkinson's disease is asymmetrical, and patients have features such as bradykinesia, tremor, postural instability, and rigidity. Autoimmune parkinsonism is rare, and often presents similar to atypical parkinsonian disorders such as multiple system atrophy (MSA), progressive supranuclear palsy (PSP), or corticobasal degeneration (CBD). Tremor is less common and other features such as eye movement abnormalities, brainstem signs, and sleep disorders are more common. Rarely parkinsonism has been described with ANNA-2 (Ri), CRMP-5, DPPX, GAD65, Ma1/Ma 2, or GlyR antibodies, and may be mistaken clinically for PSP, MSA, or CBD.<sup>75,92-96</sup>



Autoimmune mimics of CBD and MSA have been specifically reported with GAD65 antibodies. Imaging may show T2 hyperintensities in the thalamus and hypothalamus, temporal lobe, brainstem (with Ma2 antibodies), and the basal ganglia (with CRMP-5 antibodies).<sup>22</sup> Anti-Ma2 encephalitis is the classical cause of autoimmune parkinsonism;<sup>92,95</sup> this condition causes a progressive rostrocaudal rhombencephalitis with prominent sleep disorders and brainstem signs. Young men who present with this disorder almost always have testicular germ cell tumors.<sup>95</sup> In older patients, the neoplastic associations of Ma2 include breast cancer, non-SCLC, tonsillar carcinoma, lymphoma, and pancreatic and renal carcinoma, and these malignancies often coexist with Ma1 antibodies in addition to the Ma2 antibodies.<sup>29,49</sup> The parkinsonism may be levodopa-responsive in rare cases, but immune therapy responsiveness is limited.

Nonparaneoplastic autoimmune parkinsonism has been reported in association with antibodies to GAD65,<sup>93</sup> GlyR,<sup>94</sup> LGI1,<sup>97</sup> and NMDAR.<sup>98</sup> These may have a slightly more favorable response to immune therapy. Thyroid peroxidase antibodies of unclear significance have been reported in a subset of patients with multiple system atrophy-cerebellar type (MSA-C)<sup>99</sup> presentations, and several cases of parkinsonism in association with Sjögren's syndrome have also been reported.<sup>100</sup> IgLON5 antibodies have been reported in a single patient with a PSP presentation.<sup>53</sup>

### Stiff Person Syndrome/PERM

SPS is a spectrum of chronic disorders characterized by progressive rigidity and stiffness with superimposed spasms, resulting in postural deformities.

When positive, electromyogram (EMG) reveals continuous co-contraction of agonistic and antagonistic muscles with accompanying sustained motor unit action potentials.<sup>56</sup> The condition occurs without any visible fasciculations or myokymias, and responds to peripheral nerve blockade (unlike neuromyotonia). The prevalence is estimated to be 1 in 1,250,000<sup>101</sup> with a female preponderance of 7:3 and a median age of onset of 40 years, occurring rarely in childhood.<sup>102</sup>

SPS is primarily associated with antibodies which target GABAergic and glycinergic transmission. The most commonly occurring antibody in SPS is GAD65.<sup>102</sup> GAD65 is an intracellular synaptic protein, and therefore the antibodies are unlikely to be pathogenic but rather a biomarker of an associated cytotoxic T cell-mediated immune response. This antibody is also found in association with other autoimmune disorders such as type 1 diabetes mellitus. Serum GAD65 levels are significantly lower (less than 20 nmol/L) in patients with diabetes without features of SPS.<sup>103,104</sup> Detection of GAD65 in the CSF is specific for immune-mediated neurological diseases.<sup>105</sup> The next most common antibody is the GlyR (GlyR $\alpha$ 1) antibody.<sup>106</sup> Other antibodies associated with the syndrome include amphiphysin, DPPX, GABA-A, GABA-A receptor-associated protein (GABARAP), and gephyrin. GABARAP is always found with GAD65 present, so we have not included it in our table. Gephyrin has only been described in one report to date.<sup>107</sup> The above antibodies appear to mediate CNS hyperexcitability by interfering with

predominantly GABAergic inhibitory mechanisms: GAD65 antibodies functionally impair GABAergic neurons,<sup>108</sup> GlyR antibodies bind to and impair receptor function on the brainstem and spinal cord motor neurons,<sup>109</sup> and amphiphysin antibodies alter the function of inhibitory synapses, leading to reduced presynaptic GABAergic inhibition.<sup>110</sup>

Clinical features include trunk and limb stiffness, painful spasms, and an exaggerated startle response (hyperekplexia). The "board-like" stiffness characteristic of classic SPS is usually symmetrical with proximal lower limbs most affected. Limited forms of the disease can occur, particularly in the setting of amphiphysin antibodies.<sup>111</sup> Hyperactivity of agonistic and antagonistic (and particularly paraspinal) muscles may be evident on examination. Over time, fixed deformities of the spine (e.g., hyperlordosis) may be apparent due to prolonged persistent muscle activity. Symptomatic improvement is seen with diazepam.<sup>112</sup> There is a spectrum of CNS hyperexcitability seen in SPS, with the most severe phenotype characterized by progressive encephalomyelitis, rigidity, and myoclonus (PERM).<sup>113</sup> These patients present with a rapidly progressive encephalopathy, rigidity characteristic of SPS, autonomic dysfunction, brainstem and spinal cord signs including bulbar and extraocular disturbances, and stimulus-sensitive myoclonus. The disorder can be fatal if untreated.<sup>114</sup>

As noted above, GAD65 is usually associated with classic SPS, but has been reported with PERM and limited forms of SPS.<sup>102</sup> In addition, it can coexist with cerebellar ataxia, chorea, myelopathy, epilepsy, and brainstem and extrapyramidal syndromes.<sup>93,115</sup> Generally, GAD65 SPS is nonparaneoplastic, although thyroid, thymus, renal, colon cancers, and lymphoma have been found.<sup>102,116–118</sup> GlyR antibodies are more common in PERM, but can also present as classic SPS.<sup>36</sup> GlyR antibodies can be nonparaneoplastic and, less frequently, paraneoplastic (in association with lymphoma and thymoma).<sup>109,119</sup> Amphiphysin is more frequently paraneoplastic and associated with breast carcinoma and SCLC, and can also cause myelopathy, encephalopathy, cerebellar dysfunction, autonomic dysfunction, and neuropathy.<sup>102,120,121</sup> DPPX is a cell surface antibody associated with a wide spectrum of multifocal neurological disorders, including SPS, but also sleep disorders, autonomic dysfunction (particularly of the gastrointestinal tract), encephalopathy, brainstem syndromes, tremor, and myelopathy.<sup>75</sup> When SPS is present in association with DPPX, it is more frequently the PERM phenotype.<sup>122</sup> Severe prodromal weight loss with diarrhea is often seen, but in most cases, there is no associated malignancy outside of rare B cell neoplasms.<sup>75</sup> GABA-A receptor-mediated disease is usually nonneoplastic and multifocal presenting with seizures, encephalopathy, OMS, and SPS.<sup>89</sup> Antibodies to gephyrin have been reported in a single patient with classic SPS and mediastinal cancer.<sup>107</sup> Clearly, the range of autoantibodies and the clinical and oncologic spectrum of these disorders remains to be fully defined.

Electrophysiological assessment may provide supportive evidence of hyperexcitability when SPS is suspected. Exaggerated acoustic startle reflexes, excessive, poorly habituating widespread motor activity, and simultaneous continuous motor unit activity of antagonistic muscles can be seen with concentric needle EMG.<sup>104</sup> GAD65-mediated SPS has a variable

response to immunotherapy, and responses do not correlate with antibody titers. Complete response to treatment is uncommon, and the disease may demonstrate a progressive course despite symptomatic improvement with diazepam.<sup>104</sup> If patients do respond dramatically to immunotherapy, they are more likely to have GlyR or other cell surface antibodies such as DPPX or GABA-A. Although amphiphysin is an intracellular antigen, some patients respond with treatment of the underlying cancer and immunotherapy, and thus a trial of treatment is warranted in such cases.<sup>110</sup>

### Tremor

Tremor is an involuntary periodic (usually sinusoidal) oscillation of a part of the body. Tremor rarely occurs in the setting of autoimmune parkinsonism, but can occur as part of an autoimmune encephalitis. Recognized antibodies that are

associated with tremor include AMPAR, CASPR2, DPPX, GABAR-B, GFAP, Glycine R, LGI1, mGluR1, NMDAR, PQ, and N-type calcium channel antibodies.<sup>21,37,47,74,75,123</sup>

### Pediatric Movement Disorders and Controversies

SC occurs 4 to 8 weeks following group A  $\beta$ -hemolytic streptococcal infection. It occurs in 25% of children with rheumatic fever.<sup>124</sup> The peak age of onset is 8 to 9 years of age and it is rarely seen under 5 years.<sup>124</sup> A recent Irish study suggested the incidence is increasing (0.23/100,000).<sup>125</sup> SC tends to generalize but is typically asymmetric; and pure hemichorea can be seen in 20% of cases.<sup>124,126</sup> Additional features are often seen including motor imperistence, hypometric saccades, and hypotonia.<sup>126</sup> In severe cases, the hypotonia may be so severe as to render the patient bedridden (chorea paralytica).

**Table 4** Immunotherapy options

Treatment	Suggested regimen	Acute/chronic	Side effects	Additional
Immunoglobulin	0.4 g/kg/d IV $\times$ 5 days followed by repeat infusions every month	Acute and/or chronic	Anaphylaxis, aseptic meningitis, renal failure, thrombosis	Check for IgA deficiency pre use
Methylprednisolone/prednisolone	1 g daily $\times$ 5 days with option to repeat intermittently or 60 mg daily orally reducing dose	Acute and/or chronic	Avascular necrosis, Cushing's syndrome, hypertension, hyperglycemia, hypokalemia, insomnia, mania, psychosis, osteoporosis, peripheral edema, peptic ulcer disease	Glucose monitoring PPI for stomach protection DEXA scan if long-term use Bone protection with calcium/vitamin D/bisphosphonate as appropriate
Plasmapheresis	1 $\times$ 2–3 L IV exchange alternate days $\times$ 5–7 treatments, can be repeated 2–3 monthly	Acute and/or chronic	Bleeding, hypocalcaemia, hypotension, hypoalbuminemia, hypofibrinogenemia. Requires large-bore line.	Daily albumin, electrolytes and fibrinogen, replace as appropriate
Azathioprine	1.5 mg/kg/d orally increasing to 2.5 mg/kg/d over time	Chronic, steroid sparing	Alopecia, diarrhea, nausea, hepatitis, infections, lymphoma after long-term use, teratogenic	Check TPMT levels if low adjust dose Septrin prophylaxis 960 mg $\times$ 3/week Yearly Influenza vaccine Pneumococcus vaccine every 5 years
Cyclophosphamide	1–2 mg/kg/d orally or 500–1,000 mg/M2/month IV $\times$ 6 months	Chronic	Alopecia, hemorrhagic cystitis, infertility, leukopenia (nadir by day 14), mucositis, nausea, thrombocytopenia, vomiting	Pretreatment antiemetic, hydration, MESNA Particularly paraneoplastic cases
Mycophenolate mofetil	500 mg orally twice daily, build up to 1,000 mg orally twice daily	Chronic steroid sparing	Bronchiectasis, diarrhea, hepatotoxicity, hypertension, hypogammaglobulinemia, infection, lymphopenia, lymphoma after long-term use, nausea, peripheral edema, teratogenic, vomiting	Septrin prophylaxis 960 mg $\times$ 3/week Yearly Influenza vaccine Pneumococcus vaccine every 5 years
Rituximab	1,000 mg IV $\times$ 2 doses 14 days apart, repeat every 6 months or follow CD19 cell count		Hypogammaglobulinemia	Pretreatment immunoglobulin levels, HBV, HCV, QuantiFERON, pretreatment influenza vaccine

Abbreviations: DEXA, dual energy X-ray absorptiometry; HBV, Hepatitis B virus; HCV, Hepatitis C virus; IgA, immunoglobulin A; IV, intravenous; MESNA, Uromitexan; PPI, proton pump inhibitor; TPMT, thiopurine methyltransferase

Tics are often reported with SC but can be difficult to distinguish from chorea. Tics are repetitive stereotyped movements or vocalizations that are brief, including blinking, coughing, grunting, shrugging, and sniffing. They can be simple or complex, encompassing multiple tics in sequence. Adult-onset SC is rare.

A wealth of behavioral disturbances are associated with SC, in particular obsessive compulsive behavior and attention and anxiety disorders.<sup>127</sup> There is evidence that executive dysfunction, particularly verbal fluency, occurs in patients with SC, implicating the prefrontal cortex (as well as the basal ganglia) in this disease.<sup>128</sup> Pediatric acute neuropsychiatric syndrome (PANS) and pediatric autoimmune neuropsychiatric disorders associated with streptococcus infection (PANDAS) are related entities, which consist of tics, obsessive compulsive disorder, and psychiatric symptoms following streptococcal infection. Although an autoimmune pathogenesis (i.e., molecular mimicry) has been presumed in SC, no definite antigen has been identified to date. Elevations in several autoantibodies antibodies have been proposed in SC but these antibodies are also found in healthy controls, Huntington's disease, and Parkinson's disease.<sup>129–131</sup> Antibody testing in PANS and PANDAS tends to be negative.<sup>132</sup> SC is often self-limiting, albeit after many months or a few years, but it can recur.<sup>133</sup> Pediatric autoimmune disorders are covered in a separate article in this journal.

### Treatment of Autoimmune Movement Disorders

There have been no randomized controlled trials of treatment of autoimmune movement disorders. Generally, symptomatic medications that would be used in chorea and parkinsonism, for example, tetrabenazine or L-dopa, will not alter the disease course. In SPS, medications that enhance GABAergic transmission such as diazepam, tizanidine, or baclofen/lioresal may improve symptoms in mild disease; in severe disease, immunotherapy is warranted. Acute first-line therapy is dependent on the treatment center and availability. Intravenous pulsed steroids, intravenous immunoglobulin, and plasmapheresis are all frequently used, reasonable options. Depending on the condition, etiology, and antibody identified, consideration should be given to second-line immunotherapy for several years, especially if the disorder is known to relapse, as in nonteratoma-associated NMDAR disorders. Paraneoplastic cerebellar ataxia often is monophasic and therefore a short course of cytotoxic therapy after cancer treatment for 3 to 6 months may stabilize the patient. Disorders such as OMS usually do well with short courses of treatment. ► **Table 4** lists all the commonly used immunotherapies to date. In addition, other agents such as tocilizumab (IL-6 inhibitor) and bortezomib (plasma cell depletor) have been used in isolated refractory NMDAR encephalitis cases.<sup>132–135</sup> Another exciting new therapeutic option in early-phase experimentation may be ephrin B2, which has been administered to mice together with NMDAR antibody-positive CSF with a resultant reduction in memory and behavior disruption by the NMDAR antibodies.<sup>29,49,101,135,136</sup>

## Conclusion

Isolated autoimmune movement disorders are rare and most commonly occur with other neurological features. Suspicion of these disorders should prompt a thorough investigation for an identifiable cancer and associated neural or systemic antibodies. This will aid decisions with regard to treatment and prognosis. Disorders with an extracellular antibody and without cancer are more likely to respond to treatment. Disorders with a cancer and/or an intracellular antibody respond less well to immunotherapy.

### Ethical Statement

We confirm that we have read the journal's position on issues involved in ethical publication and affirm that this report is consistent with those guidelines.

### Conflicts of Interest

None.

### Acknowledgments

None.

## References

- 1 Brain WR, Daniel PM, Greenfield JG. Subacute cortical cerebellar degeneration and its relation to carcinoma. *J Neurol Neurosurg Psychiatry* 1951;14(02):59–75
- 2 Ross AT, Zeman W. Opsoclonus, occult carcinoma, and chemical pathology in dentate nuclei. *Arch Neurol* 1967;17(05):546–551
- 3 Platt MP, Agalliu D, Cutforth T. Hello from the other side: how autoantibodies circumvent the blood-brain barrier in autoimmune encephalitis. *Front Immunol* 2017;8:442
- 4 McKeon A, Pittock SJ. Paraneoplastic encephalomyelopathies: pathology and mechanisms. *Acta Neuropathol* 2011;122(04):381–400
- 5 Graus F, Saiz A, Dalmau J. Antibodies and neuronal autoimmune disorders of the CNS. *J Neurol* 2010;257(04):509–517
- 6 Grant R, Graus F. Paraneoplastic movement disorders. *Mov Disord* 2009;24(12):1715–1724
- 7 Mehta SH, Morgan JC, Sethi KD. Paraneoplastic movement disorders. *Curr Neurol Neurosci Rep* 2009;9(04):285–291
- 8 Stich O, Jarius S, Kleer B, Rasiah C, Voltz R, Rauer S. Specific antibody index in cerebrospinal fluid from patients with central and peripheral paraneoplastic neurological syndromes. *J Neuroimmunol* 2007;183(1–2):220–224
- 9 Linnoila J, Pittock SJ. Autoantibody-associated central nervous system neurologic disorders. *Semin Neurol* 2016;36(04):382–396
- 10 Dalmau J, Rosenfeld MR. Autoimmune encephalitis update. *Neuro-oncol* 2014;16(06):771–778
- 11 O'Toole O, Clardy S, Lin Quek AM. Paraneoplastic and autoimmune encephalopathies. *Semin Neurol* 2013;33(04):357–364
- 12 Albert ML, Austin LM, Darnell RB. Detection and treatment of activated T cells in the cerebrospinal fluid of patients with paraneoplastic cerebellar degeneration. *Ann Neurol* 2000;47(01):9–17
- 13 Vernino S, O'Neill BP, Marks RS, O'Fallon JR, Kimmel DW. Immunomodulatory treatment trial for paraneoplastic neurological disorders. *Neuro-oncol* 2004;6(01):55–62
- 14 Lancaster E, Martinez-Hernandez E, Dalmau J. Encephalitis and antibodies to synaptic and neuronal cell surface proteins. *Neurology* 2011;77(02):179–189

- 15 Lai M, Huijbers MGM, Lancaster E, et al. Investigation of LGI1 as the antigen in limbic encephalitis previously attributed to potassium channels: a case series. *Lancet Neurol* 2010;9(08):776–785
- 16 Hughes EG, Peng X, Gleichman AJ, et al. Cellular and synaptic mechanisms of anti-NMDA receptor encephalitis. *J Neurosci* 2010;30(17):5866–5875
- 17 Graus F, Saiz A, Lai M, et al. Neuronal surface antigen antibodies in limbic encephalitis: clinical-immunologic associations. *Neurology* 2008;71(12):930–936
- 18 McKeon A, Pittock SJ, Lennon VA. CSF complements serum for evaluating paraneoplastic antibodies and NMO-IgG. *Neurology* 2011;76(12):1108–1110
- 19 Titulaer MJ, McCracken L, Gabilondo I, et al. Treatment and prognostic factors for long-term outcome in patients with anti-NMDA receptor encephalitis: an observational cohort study. *Lancet Neurol* 2013;12(02):157–165
- 20 Psimaras D, Carpentier AF, Rossi C; PNS Euronetwork. Cerebrospinal fluid study in paraneoplastic syndromes. *J Neurol Neurosurg Psychiatry* 2010;81(01):42–45
- 21 Flanagan EP, Hinson SR, Lennon VA, et al. Glial fibrillary acidic protein immunoglobulin G as biomarker of autoimmune astrocytopathy: Analysis of 102 patients. *Ann Neurol* 2017;81(02):298–309
- 22 McKeon A, Ahlskog JE, Britton JW, Lennon VA, Pittock SJ. Reversible extralimbic paraneoplastic encephalopathies with large abnormalities on magnetic resonance images. *Arch Neurol* 2009;66(02):268–271
- 23 Irani SR, Michell AW, Lang B, et al. Faciobrachial dystonic seizures precede Lgi1 antibody limbic encephalitis. *Ann Neurol* 2011;69(05):892–900
- 24 Schmitt SE, Pargeon K, Frechette ES, Hirsch LJ, Dalmau J, Friedman D. Extreme delta brush: a unique EEG pattern in adults with anti-NMDA receptor encephalitis. *Neurology* 2012;79(11):1094–1100
- 25 McKeon A, Apiwatanakul M, Lachance DH, et al. Positron emission tomography-computed tomography in paraneoplastic neurologic disorders: systematic analysis and review. *Arch Neurol* 2010;67(03):322–329
- 26 Titulaer MJ, Soffietti R, Dalmau J, et al; European Federation of Neurological Societies. Screening for tumours in paraneoplastic syndromes: report of an EFNS task force. *Eur J Neurol* 2011;18(01):19–e3
- 27 Dalmau J, Tüzün E, Wu HY, et al. Paraneoplastic anti-N-methyl-D-aspartate receptor encephalitis associated with ovarian teratoma. *Ann Neurol* 2007;61(01):25–36
- 28 Peterson K, Rosenblum MK, Kotanides H, Posner JB. Paraneoplastic cerebellar degeneration. I. A clinical analysis of 55 anti-Yo antibody-positive patients. *Neurology* 1992;42(10):1931–1937
- 29 Honorat JA, McKeon A. Autoimmune movement disorders: a clinical and laboratory approach. *Curr Neurol Neurosci Rep* 2017;17(01):4
- 30 Esposito M, Penza P, Orefice G, et al. Successful treatment of paraneoplastic cerebellar degeneration with rituximab. *J Neurooncol* 2008;86(03):363–364
- 31 McKeon A, Tracy JA, Pittock SJ, Parisi JE, Klein CJ, Lennon VA. Purkinje cell cytoplasmic autoantibody type 1 accompaniments: the cerebellum and beyond. *Arch Neurol* 2011;68(10):1282–1289
- 32 Bürk K, Wick M, Roth G, Decker P, Voltz R. Antineuronal antibodies in sporadic late-onset cerebellar ataxia. *J Neurol* 2010;257(01):59–62
- 33 Saiz A, Arpa J, Sagasta A, et al. Autoantibodies to glutamic acid decarboxylase in three patients with cerebellar ataxia, late-onset insulin-dependent diabetes mellitus, and polyendocrine autoimmunity. *Neurology* 1997;49(04):1026–1030
- 34 Ariño H, Höftberger R, Gresa-Arribas N, et al. Paraneoplastic neurological syndromes and glutamic acid decarboxylase antibodies. *JAMA Neurol* 2015;72(08):874–881
- 35 Baizabal-Carvallo JF, Alonso-Juarez M. Cerebellar disease associated with anti-glutamic acid decarboxylase antibodies: review. *J Neural Transm (Vienna)* 2017;124(10):1171–1182
- 36 Martinez-Hernandez E, Ariño H, McKeon A, et al. Clinical and immunologic investigations in patients with stiff-person spectrum disorder. *JAMA Neurol* 2016;73(06):714–720
- 37 Fang B, McKeon A, Hinson SR, et al. Autoimmune glial fibrillary acidic protein astrocytopathy: a novel meningoencephalomyelitis. *JAMA Neurol* 2016;73(11):1297–1307
- 38 Joubert B, Gobert F, Thomas L, et al. Autoimmune episodic ataxia in patients with anti-CASPR2 antibody-associated encephalitis. *Neurol Neuroimmunol Neuroinflamm* 2017;4(04):e371
- 39 Mitoma H, Adhikari K, Aeschlimann D, et al. Consensus paper: neuroimmune mechanisms of cerebellar ataxias. *Cerebellum* 2016;15(02):213–232
- 40 O'Toole O, Lennon VA, Ahlskog JE, et al. Autoimmune chorea in adults. *Neurology* 2013;80(12):1133–1144
- 41 Zomorodi A, Wald ER. Sydenham's chorea in western Pennsylvania. *Pediatrics* 2006;117(04):e675–e679
- 42 Vigiiani MC, Honnorat J, Antoine J-C, et al; PNS EuroNetwork. Chorea and related movement disorders of paraneoplastic origin: the PNS EuroNetwork experience. *J Neurol* 2011;258(11):2058–2068
- 43 Vernino S, Tuite P, Adler CH, et al. Paraneoplastic chorea associated with CRMP-5 neuronal antibody and lung carcinoma. *Ann Neurol* 2002;51(05):625–630
- 44 Yu Z, Kryzer TJ, Griesmann GE, Kim K, Benarroch EE, Lennon VA. CRMP-5 neuronal autoantibody: marker of lung cancer and thymoma-related autoimmunity. *Ann Neurol* 2001;49(02):146–154
- 45 Samii A, Dahlen DD, Spence AM, Maronian NC, Kraus EE, Lennon VA. Paraneoplastic movement disorder in a patient with non-Hodgkin's lymphoma and CRMP-5 autoantibody. *Mov Disord* 2003;18(12):1556–1558
- 46 Muehlschlegel S, Okun MS, Foote KD, Coco D, Yachnis AT, Fernandez HH. Paraneoplastic chorea with leukoencephalopathy presenting with obsessive-compulsive and behavioral disorder. *Mov Disord* 2005;20(11):1523–1527
- 47 Mohammad SS, Fung VSC, Grattan-Smith P, et al. Movement disorders in children with anti-NMDAR encephalitis and other autoimmune encephalopathies. *Mov Disord* 2014;29(12):1539–1542
- 48 Gresa-Arribas N, Planagumà J, Petit-Pedrol M, et al. Human neurexin-3 $\alpha$  antibodies associate with encephalitis and alter synapse development. *Neurology* 2016;86(24):2235–2242
- 49 Panzer J, Dalmau J. Movement disorders in paraneoplastic and autoimmune disease. *Curr Opin Neurol* 2011;24(04):346–353
- 50 Titulaer MJ, Leypoldt F, Dalmau J. Antibodies to N-methyl-D-aspartate and other synaptic receptors in choreoathetosis and relapsing symptoms post-herpes virus encephalitis. *Mov Disord* 2014;29(01):3–6
- 51 Armangue T, Leypoldt F, Málaga I, et al. Herpes simplex virus encephalitis is a trigger of brain autoimmunity. *Ann Neurol* 2014;75(02):317–323
- 52 Dalmau J, Gleichman AJ, Hughes EG, et al. Anti-NMDA-receptor encephalitis: case series and analysis of the effects of antibodies. *Lancet Neurol* 2008;7(12):1091–1098
- 53 Sabater L, Gaig C, Gelpi E, et al. A novel non-rapid-eye movement and rapid-eye-movement parasomnia with sleep breathing disorder associated with antibodies to IgLON5: a case series, characterisation of the antigen, and post-mortem study. *Lancet Neurol* 2014;13(06):575–586
- 54 Honorat JA, Komorowski L, Josephs KA, et al. IgLON5 antibody: Neurological accompaniments and outcomes in 20 patients. *Neurol Neuroimmunol Neuroinflamm* 2017;4(05):e385
- 55 Mohammad SS, Sinclair K, Pillai S, et al. Herpes simplex encephalitis relapse with chorea is associated with autoantibodies to N-Methyl-D-aspartate receptor or dopamine-2 receptor. *Mov Disord* 2014;29(01):117–122

- 56 Donaldson I, Marsden CD, Schneider S. *Marsden's Book of Movement Disorders*. Oxford: Oxford University Press; 2012
- 57 Pittock SJ, Parisi JE, McKeon A, et al. Paraneoplastic jaw dystonia and laryngospasm with antineuronal nuclear autoantibody type 2 (anti-Ri). *Arch Neurol* 2010;67(09):1109–1115
- 58 Greenlee JE, Clawson SA, Hill KE, et al. Neuronal uptake of anti-Hu antibody, but not anti-Ri antibody, leads to cell death in brain slice cultures. *J Neuroinflammation* 2014;11:160
- 59 Rubio-Agustí I, Dalmau J, Sevilla T, Bungal M, Beltrán E, Bataller L. Isolated hemidystonia associated with NMDA receptor antibodies. *Mov Disord* 2011;26(02):351–352
- 60 Duan B-C, Weng W-C, Lin K-L, et al. Variations of movement disorders in anti-N-methyl-D-aspartate receptor encephalitis: A nationwide study in Taiwan. *Medicine (Baltimore)* 2016;95(37):e4365
- 61 Baizabal-Carvallo JF, Stocco A, Muscal E, Jankovic J. The spectrum of movement disorders in children with anti-NMDA receptor encephalitis. *Mov Disord* 2013;28(04):543–547
- 62 Tzoulis C, Vedeler C, Haugen M, et al. Progressive striatal necrosis associated with anti-NMDA receptor antibodies. *BMC Neurol* 2013;13:55
- 63 Goldberg EM, Titulaer M, de Blank PM, Sievert A, Ryan N. Anti-N-methyl-D-aspartate receptor-mediated encephalitis in infants and toddlers: case report and review of the literature. *Pediatr Neurol* 2014;50(02):181–184
- 64 van Sonderen A, Thijs RD, Coenders EC, et al. Anti-LGI1 encephalitis: clinical syndrome and long-term follow-up. *Neurology* 2016;87(14):1449–1456
- 65 Flanagan EP, Kotsenas AL, Britton JW, et al. Basal ganglia T1 hyperintensity in LGI1-autoantibody faciobrachial dystonic seizures. *Neurol Neuroimmunol Neuroinflamm* 2015;2(06):e161
- 66 Hsu Y-T, Duann J-R, Lu M-K, Sun M-C, Tsai C-H. Polyglandular autoimmune syndrome type 4 with GAD antibody and dystonia. *Clin Neurol Neurosurg* 2012;114(07):1024–1026
- 67 Kenda J, Kojović M, Graus F, Gregorič Kramberger M. (Pseudo) hemidystonia associated with anti-glutamic acid decarboxylase antibodies—a case report. *Eur J Neurol* 2015;22(12):1573–1574
- 68 Doppler K, Schleyer B, Geis C, et al. Lockjaw in stiff-person syndrome with autoantibodies against glycine receptors. *Neurol Neuroimmunol Neuroinflamm* 2015;3(01):e186
- 69 Adhiyaman V, Meara RJ, Bhowmick BK. Antiphospholipid syndrome and dystonia-parkinsonism: need for anticoagulation. *Parkinsonism Relat Disord* 2002;8(03):215, author reply 217
- 70 Milanov I, Bogdanova D. Antiphospholipid syndrome and dystonia-parkinsonism. A case report. *Parkinsonism Relat Disord* 2001;7(02):139–141
- 71 van den Berg JS, Horstink MW, van den Hoogen FH, Oyen WJ. Dystonia; a central nervous system presentation of Sjögren's syndrome. *Mov Disord* 1999;14(02):374–375
- 72 Alonso-Navarro H, Arroyo M, Parra A, Jiménez-Jiménez FJ. Paroxysmal dystonia associated to primary Sjögren's syndrome. *Mov Disord* 2009;24(05):788–790
- 73 Iorio R, Damato V, Evoli A, et al. Clinical and immunological characteristics of the spectrum of GFAP autoimmunity: a case series of 22 patients. *J Neurol Neurosurg Psychiatry* 2018;89(02):138–146
- 74 Boronat A, Gelfand JM, Gresa-Arribas N, et al. Encephalitis and antibodies to dipeptidyl-peptidase-like protein-6, a subunit of Kv4.2 potassium channels. *Ann Neurol* 2013;73(01):120–128
- 75 Tobin WO, Lennon VA, Komorowski L, et al. DPPX potassium channel antibody: frequency, clinical accompaniments, and outcomes in 20 patients. *Neurology* 2014;83(20):1797–1803
- 76 Geschwind MD, Tan KM, Lennon VA, et al. Voltage-gated potassium channel autoimmunity mimicking creutzfeldt-jakob disease. *Arch Neurol* 2008;65(10):1341–1346
- 77 Gövert F, Witt K, Erro R, et al. Orthostatic myoclonus associated with Caspr2 antibodies. *Neurology* 2016;86(14):1353–1355
- 78 Pittock SJ, Lucchinetti CF, Lennon VA. Anti-neuronal nuclear autoantibody type 2: paraneoplastic accompaniments. *Ann Neurol* 2003;53(05):580–587
- 79 McKeon A, Pittock SJ, Glass GA, et al. Whole-body tremulousness: isolated generalized polymyoclonus. *Arch Neurol* 2007;64(09):1318–1322
- 80 Wong A. An update on opsoclonus. *Curr Opin Neurol* 2007;20(01):25–31
- 81 Armangué T, Sabater L, Torres-Vega E, et al. Clinical and immunological features of opsoclonus-myoclonus syndrome in the era of neuronal cell surface antibodies. *JAMA Neurol* 2016;73(04):417–424
- 82 Young CA, MacKenzie JM, Chadwick DW, Williams IR. Opsoclonus-myoclonus syndrome: an autopsy study of three cases. *Eur J Med* 1993;2(04):239–241
- 83 Ridley A, Kennard C, Scholtz CL, Büttner-Ennever JA, Summers B, Turnbull A. Omnipause neurons in two cases of opsoclonus associated with oat cell carcinoma of the lung. *Brain* 1987;110(Pt 6):1699–1709
- 84 Kinsbourne M. Myoclonic encephalopathy of infants. *J Neurol Neurosurg Psychiatry* 1962;25(03):271–276
- 85 Klaas JP, Ahlskog JE, Pittock SJ, et al. Adult-onset opsoclonus-myoclonus syndrome. *Arch Neurol* 2012;69(12):1598–1607
- 86 Luque FA, Furneaux HM, Ferziger R, et al. Anti-Ri: an antibody associated with paraneoplastic opsoclonus and breast cancer. *Ann Neurol* 1991;29(03):241–251
- 87 Mélé N, Hautefort C, Toledano A, Delattre J-Y, Psimaras D. Paraneoplastic opsoclonus and cerebellar ataxia related to anti-Ma2 antibody: a case report. *J Neurol* 2016;263(02):405–406
- 88 Markakis I, Alexiou E, Xifaras M, Gekas G, Rombos A. Opsoclonus-myoclonus-ataxia syndrome with autoantibodies to glutamic acid decarboxylase. *Clin Neurol Neurosurg* 2008;110(06):619–621
- 89 Petit-Pedrol M, Armangué T, Peng X, et al. Encephalitis with refractory seizures, status epilepticus, and antibodies to the GABAA receptor: a case series, characterisation of the antigen, and analysis of the effects of antibodies. *Lancet Neurol* 2014;13(03):276–286
- 90 Galli JR, Clardy SL, Paz Soldán MM. Adult-onset opsoclonus-myoclonus syndrome associated with ganglionic acetylcholine receptor autoantibody. *Neurologist* 2016;21(06):99–100
- 91 Horn AK, Büttner-Ennever JA, Wahle P, Reichenberger I. Neurotransmitter profile of saccadic omnipause neurons in nucleus raphe interpositus. *J Neurosci* 1994;14(04):2032–2046
- 92 Adams C, McKeon A, Silber MH, Kumar R. Narcolepsy, REM sleep behavior disorder, and supranuclear gaze palsy associated with Ma1 and Ma2 antibodies and tonsillar carcinoma. *Arch Neurol* 2011;68(04):521–524
- 93 Pittock SJ, Yoshikawa H, Ahlskog JE, et al. Glutamic acid decarboxylase autoimmunity with brainstem, extrapyramidal, and spinal cord dysfunction. *Mayo Clin Proc* 2006;81(09):1207–1214
- 94 Peeters E, Vanacker P, Woodhall M, Vincent A, Schrooten M, Vandenberghe W. Supranuclear gaze palsy in glycine receptor antibody-positive progressive encephalomyelitis with rigidity and myoclonus. *Mov Disord* 2012;27(14):1830–1832
- 95 Matsumoto L, Yamamoto T, Higashihara M, et al. Severe hypokinesia caused by paraneoplastic anti-Ma2 encephalitis associated with bilateral intratubular germ-cell neoplasm of the testes. *Mov Disord* 2007;22(05):728–731
- 96 Kanno S, Anandakuttan A, Mathai A, Sasikumar AN, Nambiar V. Autoimmune atypical parkinsonism - A group of treatable parkinsonism. *J Neurol Sci* 2016;362:40–46
- 97 Kurtis MM, Toledano R, García-Morales I, Gil-Nagel A. Immunomodulated parkinsonism as a presenting symptom of LGI1 antibody encephalitis. *Parkinsonism Relat Disord* 2015;21(10):1286–1287

- 98 Çoban A, Ismail Küçükali C, Bilgiç B, et al. Evaluation of incidence and clinical features of antibody-associated autoimmune encephalitis mimicking dementia. *Behav Neurol* 2014;2014:935379
- 99 Shihman B, Giladi N, Bleiberg M, Rosenberg A, Korczyn AD, Gurevich T. Elevated titers of anti-thyroperoxidase antibodies in patients with multiple system atrophy: a pilot study. *Clin Neurol Neurosurg* 2013;115(11):2348–2350
- 100 Walker RH, Spiera H, Brin MF, Olanow CW. Parkinsonism associated with Sjögren's syndrome: three cases and a review of the literature. *Mov Disord* 1999;14(02):262–268
- 101 Espay AJ, Chen R. Rigidity and spasms from autoimmune encephalomyelopathies: stiff-person syndrome. *Muscle Nerve* 2006;34(06):677–690
- 102 McKeon A, Robinson MT, McEvoy KM, et al. Stiff-man syndrome and variants: clinical course, treatments, and outcomes. *Arch Neurol* 2012;69(02):230–238
- 103 Solimena M, Folli F, Aparisi R, Pozza G, De Camilli P. Autoantibodies to GABA-ergic neurons and pancreatic beta cells in stiff-man syndrome. *N Engl J Med* 1990;322(22):1555–1560
- 104 McKeon A, Tracy JA. GAD65 neurological autoimmunity. *Muscle Nerve* 2017;56(01):15–27
- 105 Saiz A, Blanco Y, Sabater L, et al. Spectrum of neurological syndromes associated with glutamic acid decarboxylase antibodies: diagnostic clues for this association. *Brain* 2008;131(Pt 10):2553–2563
- 106 Hutchinson M, Waters P, McHugh J, et al. Progressive encephalomyelitis, rigidity, and myoclonus: a novel glycine receptor antibody. *Neurology* 2008;71(16):1291–1292
- 107 Butler MH, Hayashi A, Ohkoshi N, et al. Autoimmunity to gephyrin in Stiff-Man syndrome. *Neuron* 2000;26(02):307–312
- 108 Manto M-U, Laute M-A, Aguera M, Rogemond V, Pandolfo M, Honnorat J. Effects of anti-glutamic acid decarboxylase antibodies associated with neurological diseases. *Ann Neurol* 2007;61(06):544–551
- 109 Carvajal-González A, Leite MI, Waters P, et al. Glycine receptor antibodies in PERM and related syndromes: characteristics, clinical features and outcomes. *Brain* 2014;137(Pt 8):2178–2192
- 110 Geis C, Weishaupt A, Hallermann S, et al. Stiff person syndrome-associated autoantibodies to amphiphysin mediate reduced GABAergic inhibition. *Brain* 2010;133(11):3166–3180
- 111 Murinson BB, Guarnaccia JB. Stiff-person syndrome with amphiphysin antibodies: distinctive features of a rare disease. *Neurology* 2008;71(24):1955–1958
- 112 Howard FM Jr. A new and effective drug in the treatment of the stiff-man syndrome: preliminary report. *Proc Staff Meet Mayo Clin* 1963;38:203–212
- 113 Whiteley AM, Swash M, Urich H. Progressive encephalomyelitis with rigidity. *Brain* 1976;99(01):27–42
- 114 Crisp SJ, Balint B, Vincent A. Redefining progressive encephalomyelitis with rigidity and myoclonus after the discovery of antibodies to glycine receptors. *Curr Opin Neurol* 2017;30(03):310–316
- 115 Honnorat J, Saiz A, Giometto B, et al. Cerebellar ataxia with anti-glutamic acid decarboxylase antibodies: study of 14 patients. *Arch Neurol* 2001;58(02):225–230
- 116 McHugh JC, Murray B, Renganathan R, Connolly S, Lynch T. GAD antibody positive paraneoplastic stiff person syndrome in a patient with renal cell carcinoma. *Mov Disord* 2007;22(09):1343–1346
- 117 Hagiwara H, Enomoto-Nakatani S, Sakai K, Ugawa Y, Kusunoki S, Kanazawa I. Stiff-person syndrome associated with invasive thymoma: a case report. *J Neurol Sci* 2001;193(01):59–62
- 118 Rakocevic G, Hussain A. Stiff person syndrome improvement with chemotherapy in a patient with cutaneous T cell lymphoma. *Muscle Nerve* 2013;47(06):938–939
- 119 McKeon A, Martinez-Hernandez E, Lancaster E, et al. Glycine receptor autoimmune spectrum with stiff-man syndrome phenotype. *JAMA Neurol* 2013;70(01):44–50
- 120 Galassi G, Ariatti A, Rovati R, Genovese M, Rivasi F. Longitudinally extensive transverse myelitis associated with amphiphysin autoimmunity and breast cancer: a paraneoplastic accompaniment. *Acta Neurol Belg* 2016;116(03):395–397
- 121 Moon J, Lee S-T, Shin J-W, et al. Non-stiff anti-amphiphysin syndrome: clinical manifestations and outcome after immunotherapy. *J Neuroimmunol* 2014;274(1–2):209–214
- 122 Balint B, Jarius S, Nagel S, et al. Progressive encephalomyelitis with rigidity and myoclonus: a new variant with DPPX antibodies. *Neurology* 2014;82(17):1521–1528
- 123 Tan KM, Lennon VA, Klein CJ, Boeve BF, Pittock SJ. Clinical spectrum of voltage-gated potassium channel autoimmunity. *Neurology* 2008;70(20):1883–1890
- 124 Cardoso F, Eduardo C, Silva AP, Mota CC. Chorea in fifty consecutive patients with rheumatic fever. *Mov Disord* 1997;12(05):701–703
- 125 Crealey M, Allen NM, Webb D, et al. Sydenham's chorea: not gone but perhaps forgotten. *Arch Dis Child* 2015;100(12):1160–1162
- 126 Cardoso F. Autoimmune choreas. *J Neurol Neurosurg Psychiatry* 2017;88(05):412–417
- 127 Ridel KR, Lipps TD, Gilbert DL. The prevalence of neuropsychiatric disorders in Sydenham's chorea. *Pediatr Neurol* 2010;42(04):243–248
- 128 Beato R, Maia DP, Teixeira AL Jr, Cardoso F. Executive functioning in adult patients with Sydenham's chorea. *Mov Disord* 2010;25(07):853–857
- 129 Church AJ, Cardoso F, Dale RC, Lees AJ, Thompson EJ, Giovannoni G. Anti-basal ganglia antibodies in acute and persistent Sydenham's chorea. *Neurology* 2002;59(02):227–231
- 130 Dale RC, Merheb V, Pillai S, et al. Antibodies to surface dopamine-2 receptor in autoimmune movement and psychiatric disorders. *Brain* 2012;135(Pt 11):3453–3468
- 131 Kirvan CA, Cox CJ, Swedo SE, Cunningham MW. Tubulin is a neuronal target of autoantibodies in Sydenham's chorea. *J Immunol* 2007;178(11):7412–7421
- 132 Hesselmark E, Bejerot S. Biomarkers for diagnosis of pediatric acute neuropsychiatric syndrome (pans) - sensitivity and specificity of the Cunningham Panel. *J Neuroimmunol* 2017;312:31–37
- 133 Gurkas E, Karalok ZS, Taskin BD, et al. Predictors of recurrence in Sydenham's chorea: Clinical observation from a single center. *Brain Dev* 2016;38(09):827–834
- 134 Sveinsson O, Granqvist M, Forslin Y, et al. Successful combined targeting of B- and plasma cells in treatment refractory anti-NMDAR encephalitis. *J Neuroimmunol* 2017;312:15–18
- 135 Scheibe F, Pruss H, Mengel AM, et al. Bortezomib for treatment of therapy-refractory anti-NMDa receptor encephalitis. *Neurology* 2017;88(04):366–370
- 136 Planaguma J, Haselmann H, Mannara F, et al. Ephrin-B2 prevents N-methyl-aspartate receptor antibody effects on memory and neuroplasticity. *Ann Neurol* 2016;80(03):388–400